1st Invitational Workshop Workshop on
Body Area Network Technology and Applications
Future Directions, Technologies, Standards and Applications
June 19-20, 2011
Worcester Polytechnic Institute

* 3D LOCALIZATION OF THE DENTAL OCCLUSAL PLANE USING WiFi TECHNOLOGY

Dr. MOHAMED HANIF BUTT

Clinical Instructor in Orthodontics

Department of Developmental Biology

Harvard school of Dental Medicine

Boston, MA

Lamu

*PATE, KENYA

*LAMU, KENYA

* 3D LOCALIZATION OF THE DENTAL OCCLUSAL PLANE IN NATURAL HEAD POSITION USING WiFi TECHNOLOGY

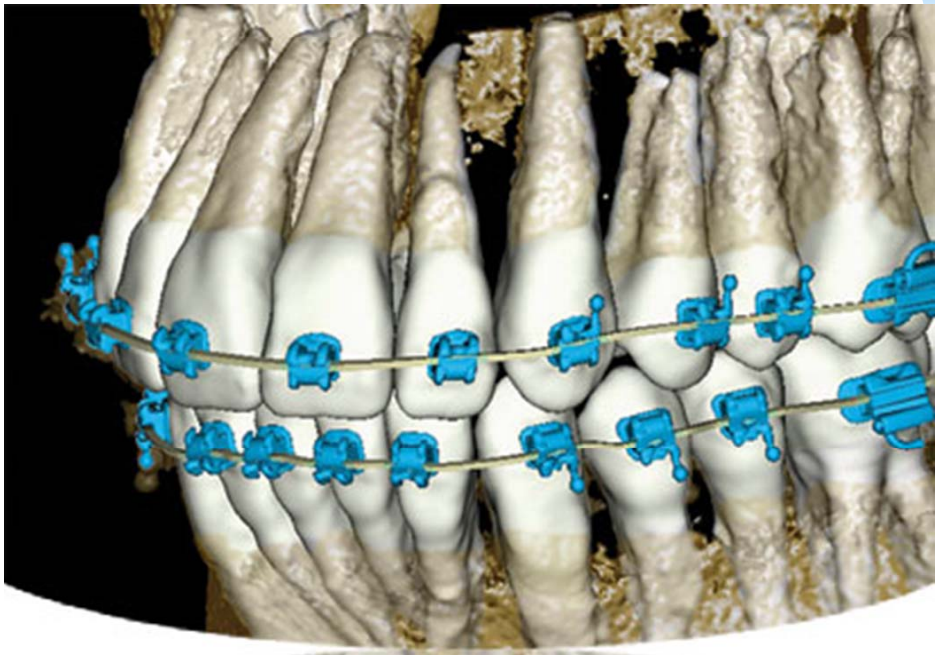

* INTRODUCTION OF LATERAL HEAD RADIOGRAPH IN 1931

ADVENT OF CEPHALOMETRICS

*

APPLICATION OF CEPHALOMETRICS

DIAGNOSIS AND TREATMENT PLANNING

GROWTH ASSESMENT/PREDICTION

EVALUATE TREATMENT CHANGES

*CHALLENGES OF CEPHALOMETRICS

* STABILITY OF THE CEPHALOMETRIC POINTS

* REPRODUCEABILITY OVER TIME TO ALLOW COMPARISON

* CEPHALOSTAT TO ORIENT THE HEAD TO THE LATERAL RADIOGRAPH

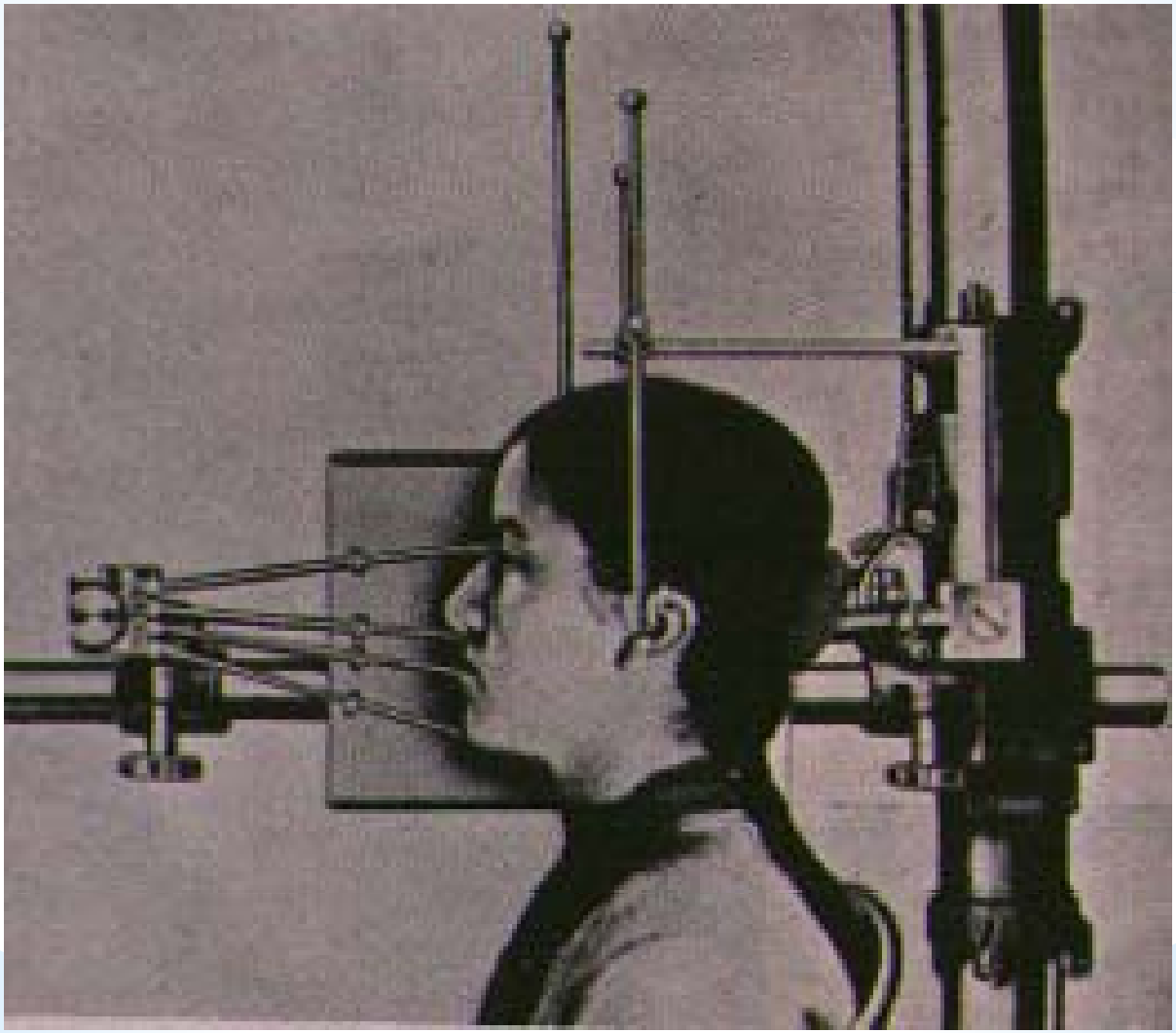

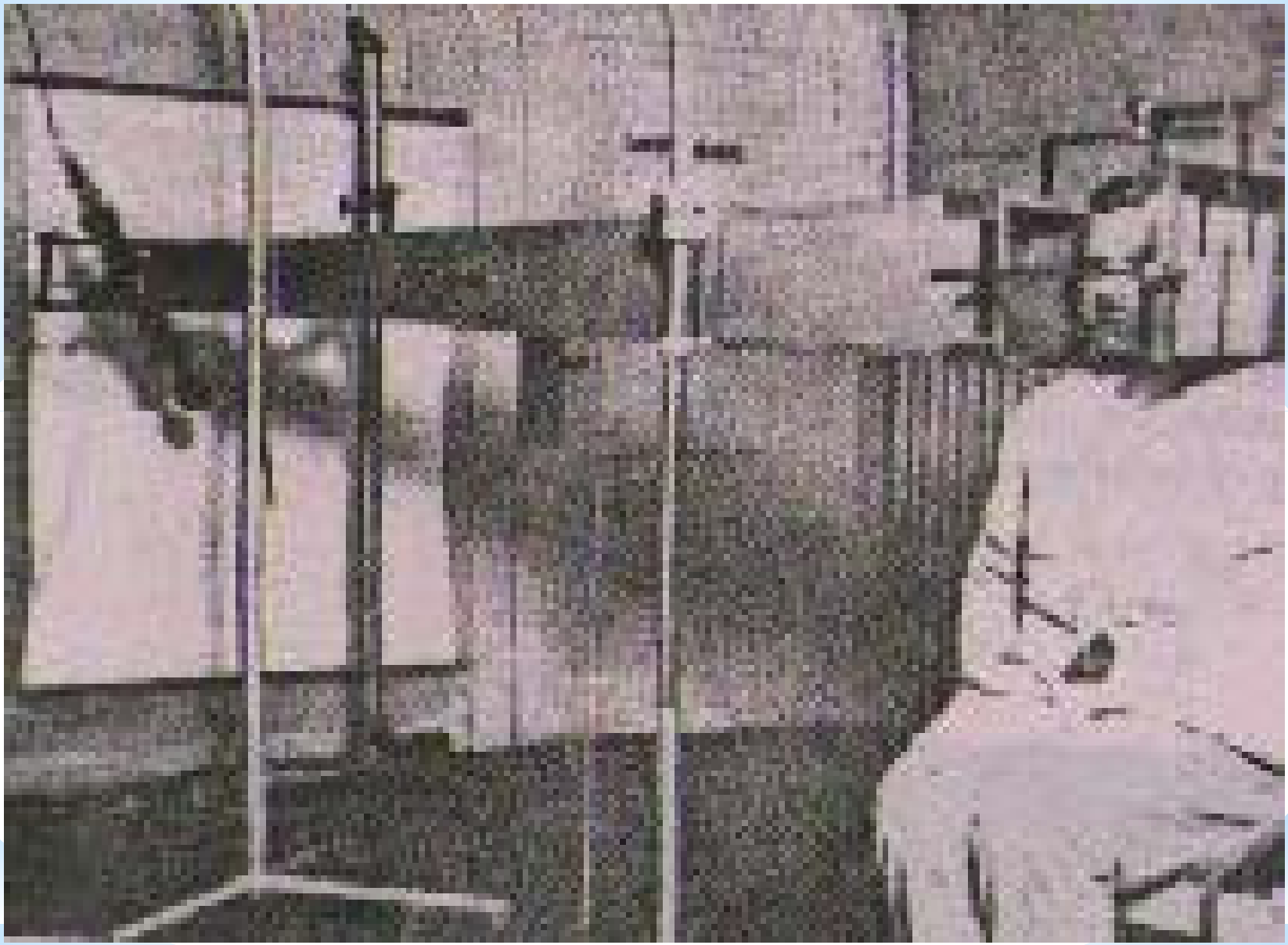

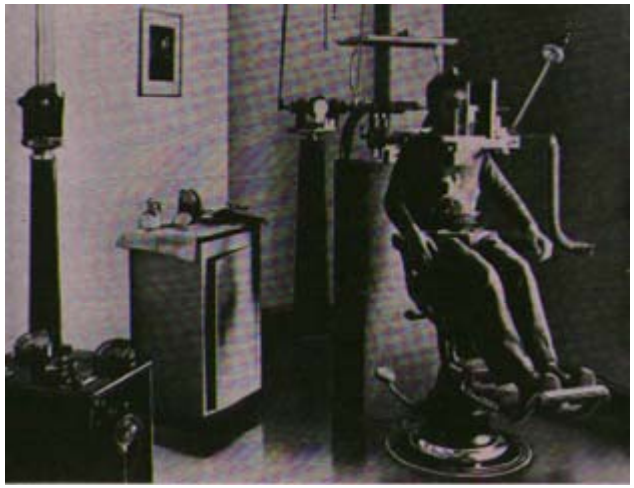



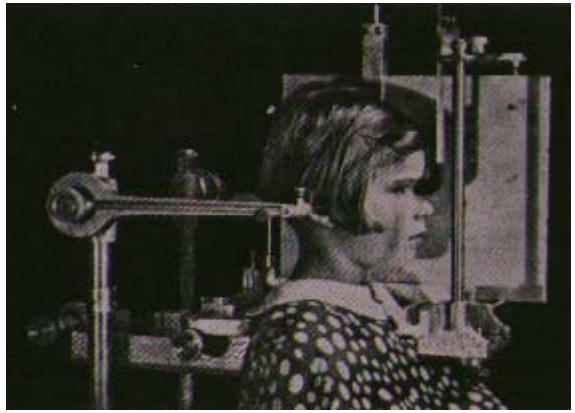

2D CEPHALOMETRIC ANALYSIS WITH TRACING PAPER ON RADIOGRAPHIC FILM

R

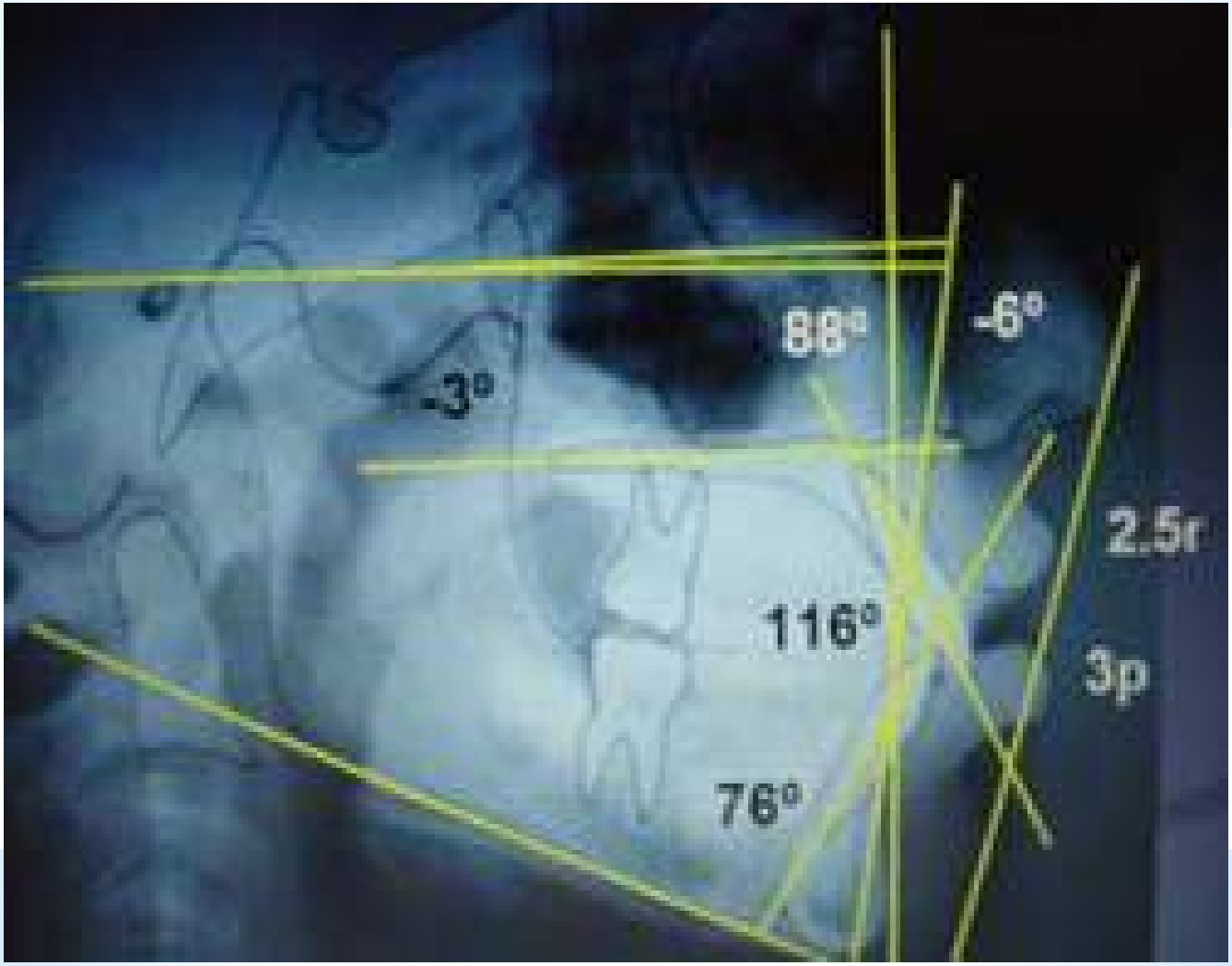

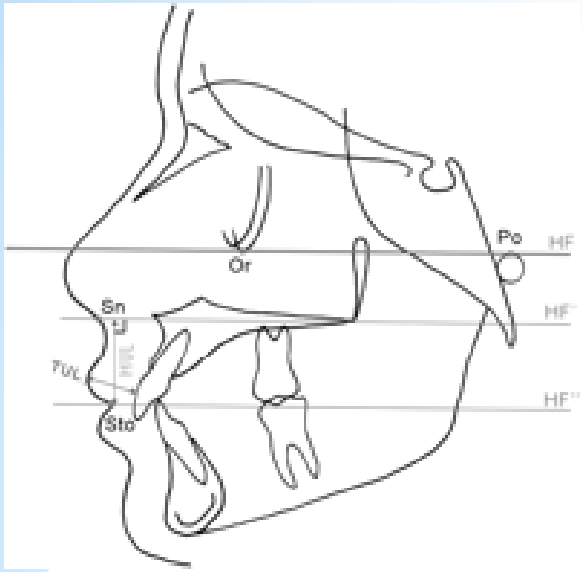
Or
Po
HF
Sn
HF'
Sto
HF''

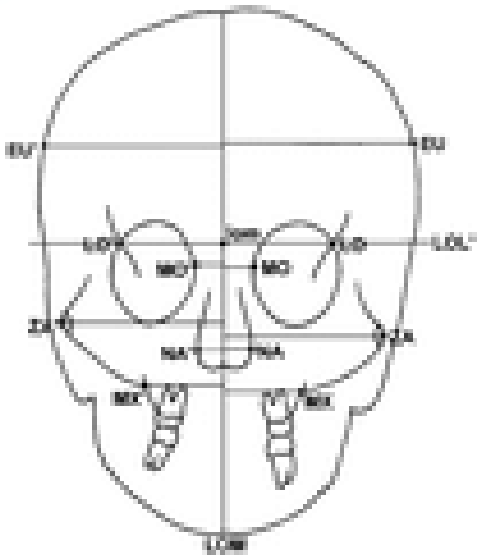
EU'
EU
LOL''
MO
MO
NA
NA
MX
MX
LOM

SO-PNS
Co-ANS
PAS
PV-A
PAS
H-SE
Co-Po
H-MP

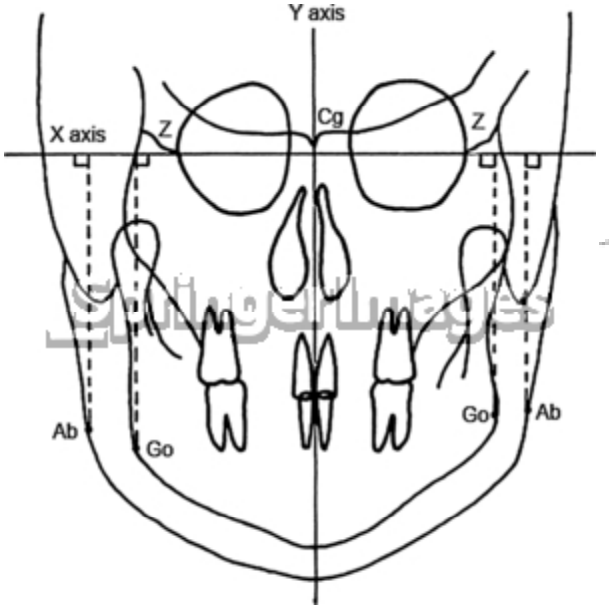
Y axis
X axis
Z
Cg
Z
Ab
Go
Go
Ab

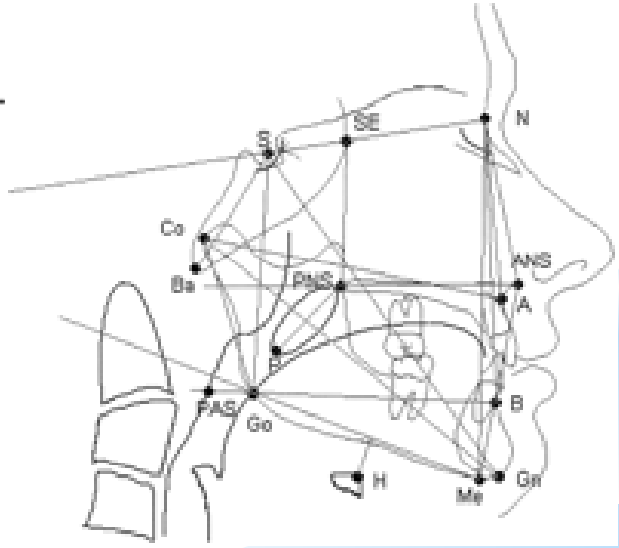
S
SE
N
Co
Ba
PNS
ANS
A
PAS
Go
B
H
Me
Gn

*STANDARDIZATION TECHNIQUES

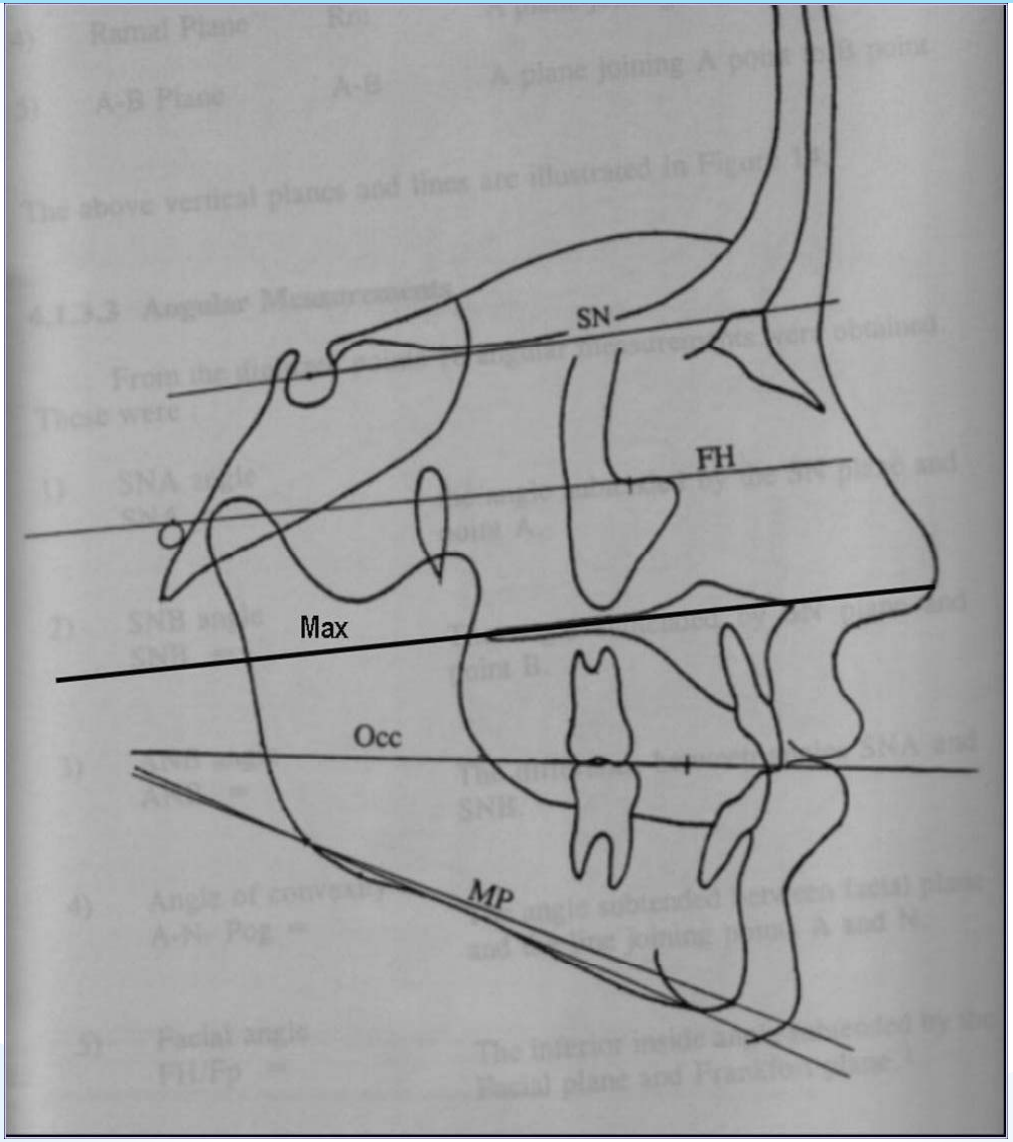

*STANDARDIZATION TECHNIQUES

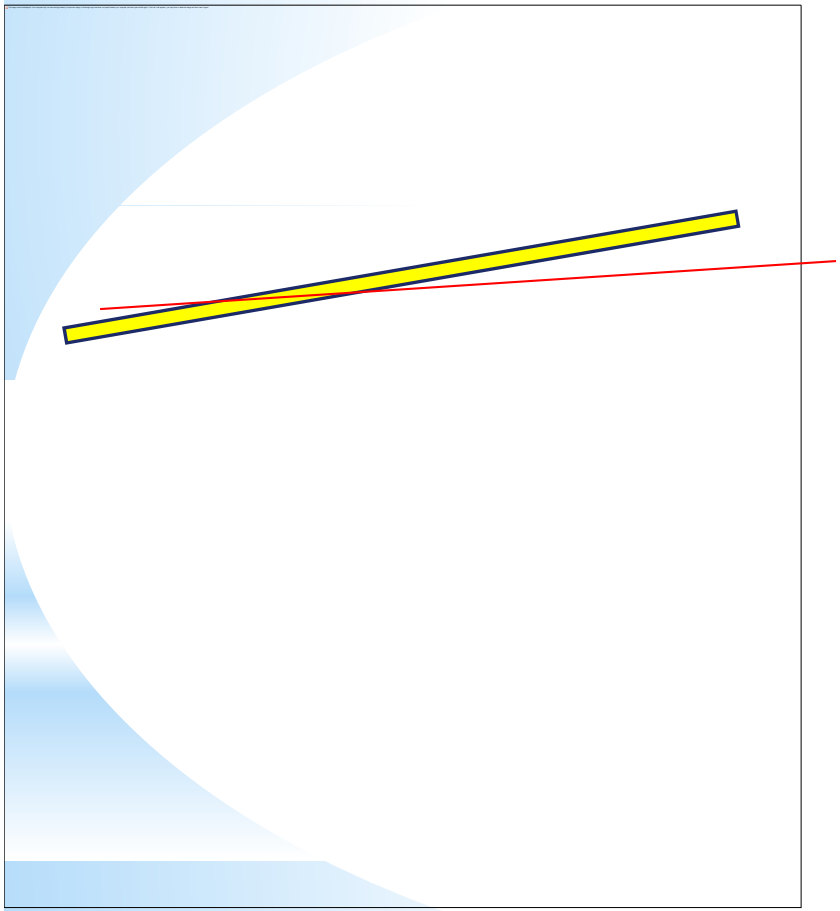

SELLA-NASION PLANE

* VERY STABLE POSITION OF CRANIAL BASE
* GROWTH COMPLET AT AGE 7 YEARS
* SN 9 DEGREES TO THE HORIZONTAL

*STANDARDIZATION TECHNIQUES

NATURAL HEAD POSITION

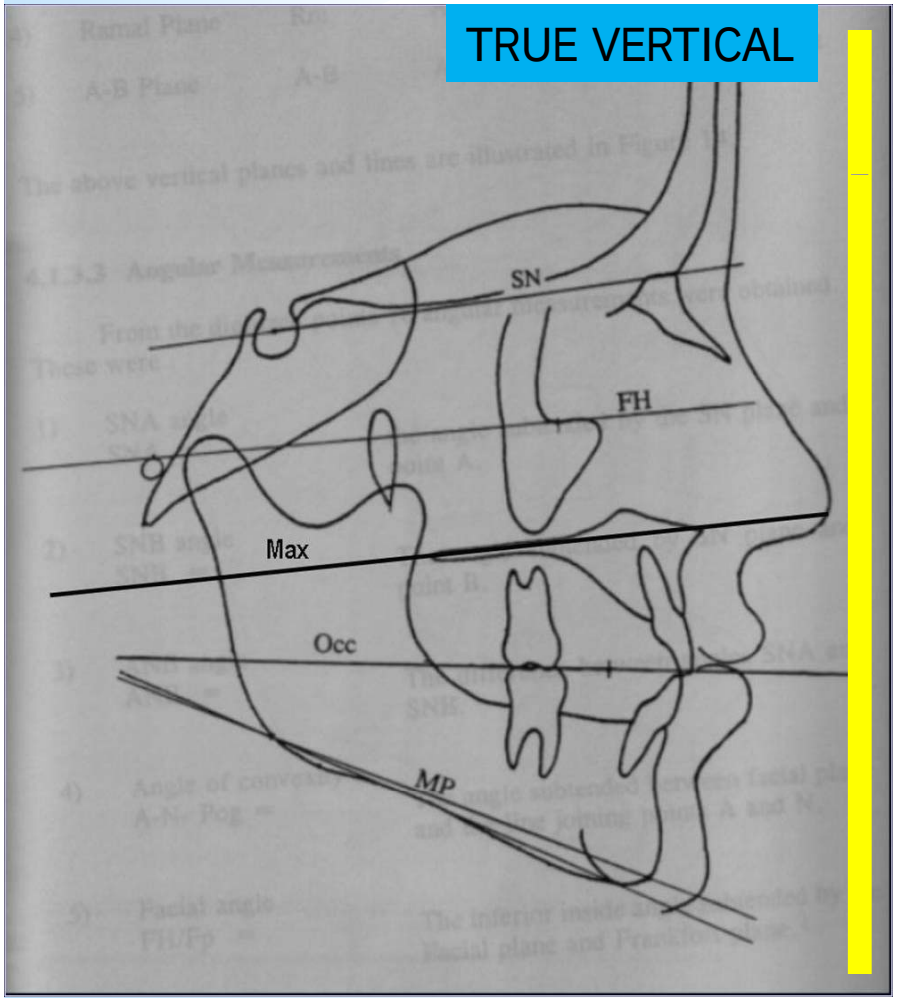

* TRUE VERTICAL
* RESTED POSITION
* PARALLEL TO FLOOR
* EYE LEVEL TO FLOOR
* SELF BALANCED BODY POSITION
* GUIDED BY MIRROR
* GUIDED BY PROFESSIONAL
* REPRODUCEABLE

* 2D CEPHALOMETRIC ANALYSIS WITH DIGITAL SOFTWARE

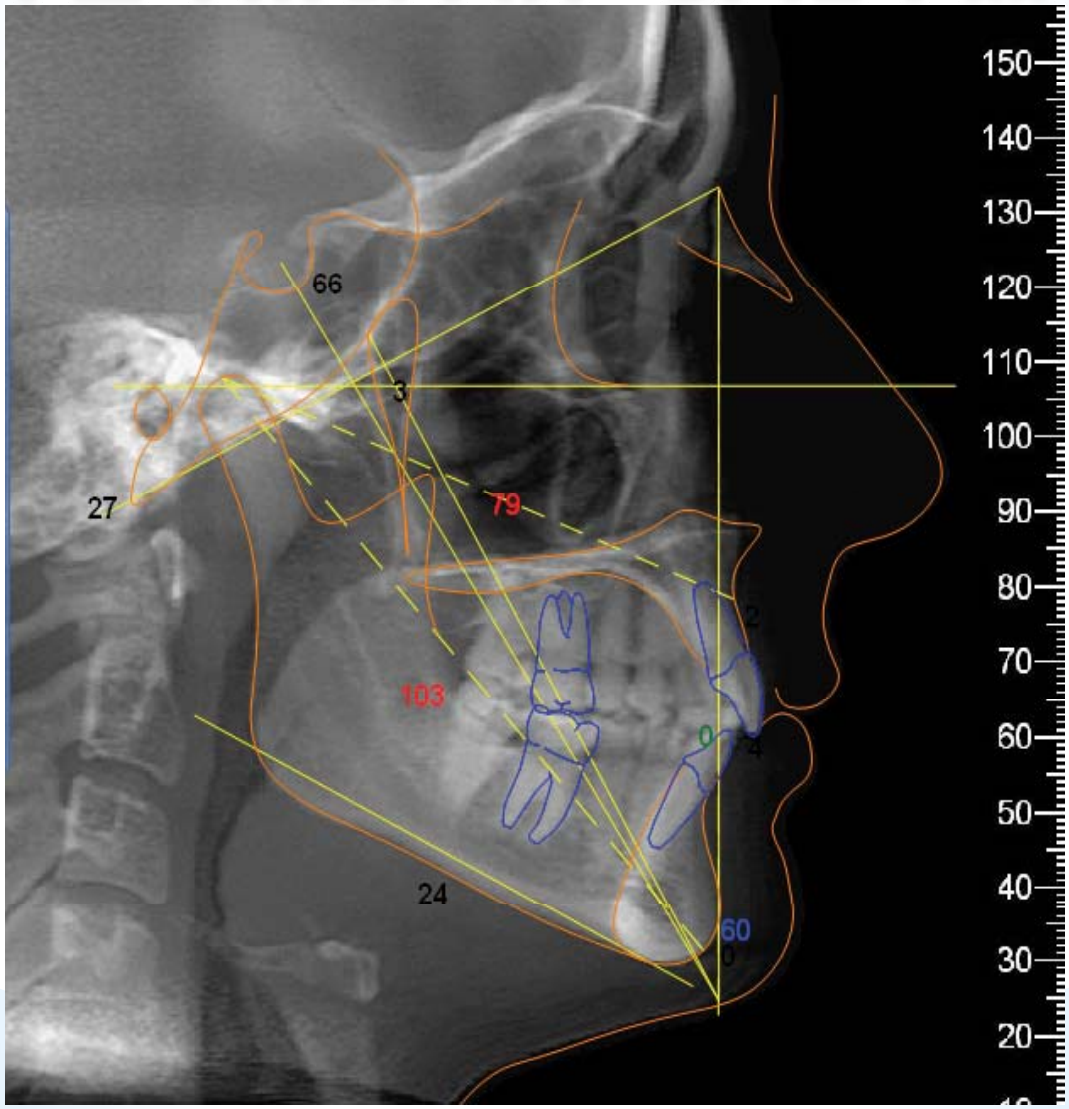

* CONCEPT OF NATURAL HEAD POSITION

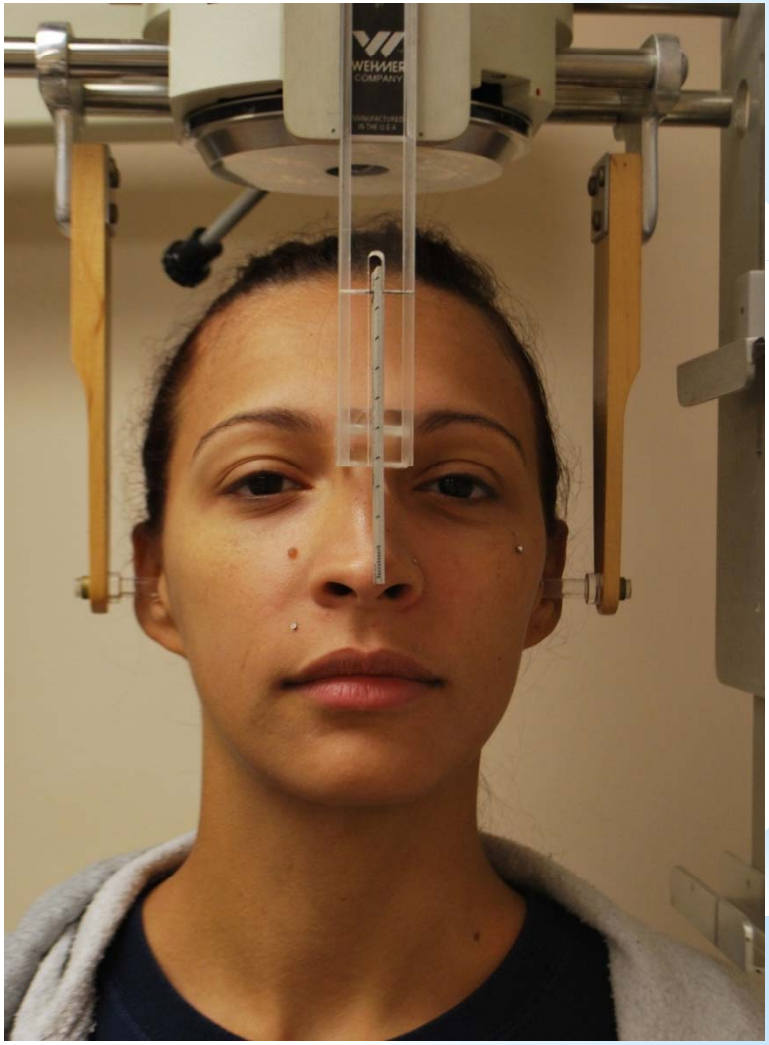

* NATURAL HEAD POSITION: SPATIAL RELATIONSHIP OF THE HEAD TO TRUE VERTICAL

* **NO WELL DEFINED STANDARDIZATION EXIST**
*
* **ELUSIVE POSITION**, VARIES FROM POSTURE TO POSTURE

* DIFFICULTY IN REPRODUCING THE POSITION

*

BODY POSTURE AND ALIGNMENT

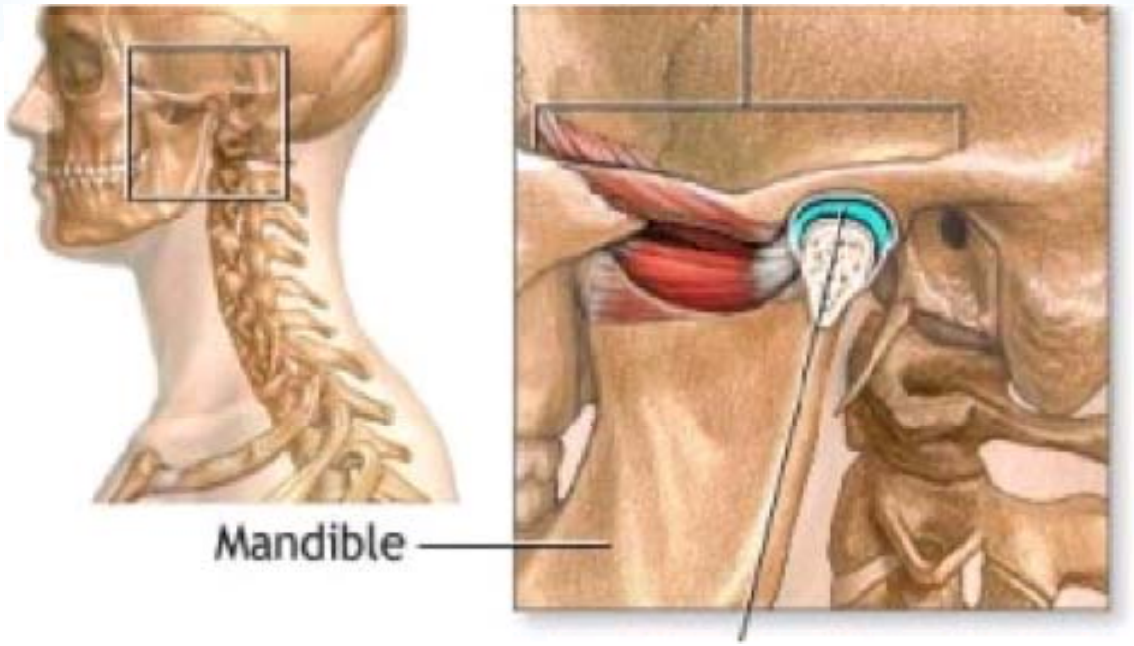

MYOCENTRIC STATE

DELICATE BALANCE OF ALL THE SKELETON AND THE NEUROMUSCULAR SYSTEMS

*POSTURAL DISORDERS

* GROWTH DISORDERS
* CRANIOFACIAL DYSMORPHOGENESIS
* CRANIOFACIAL PAIN
* SPINAL CORD DISORDERS
* OBSTRTUCTIVE SLEEP APNEA
* TEMPEROMANDIBULAR JOINT DYSFUNCTION
* OCCLUSAL DISHARMONY
* PERIODONTIUM BREAKDOWN

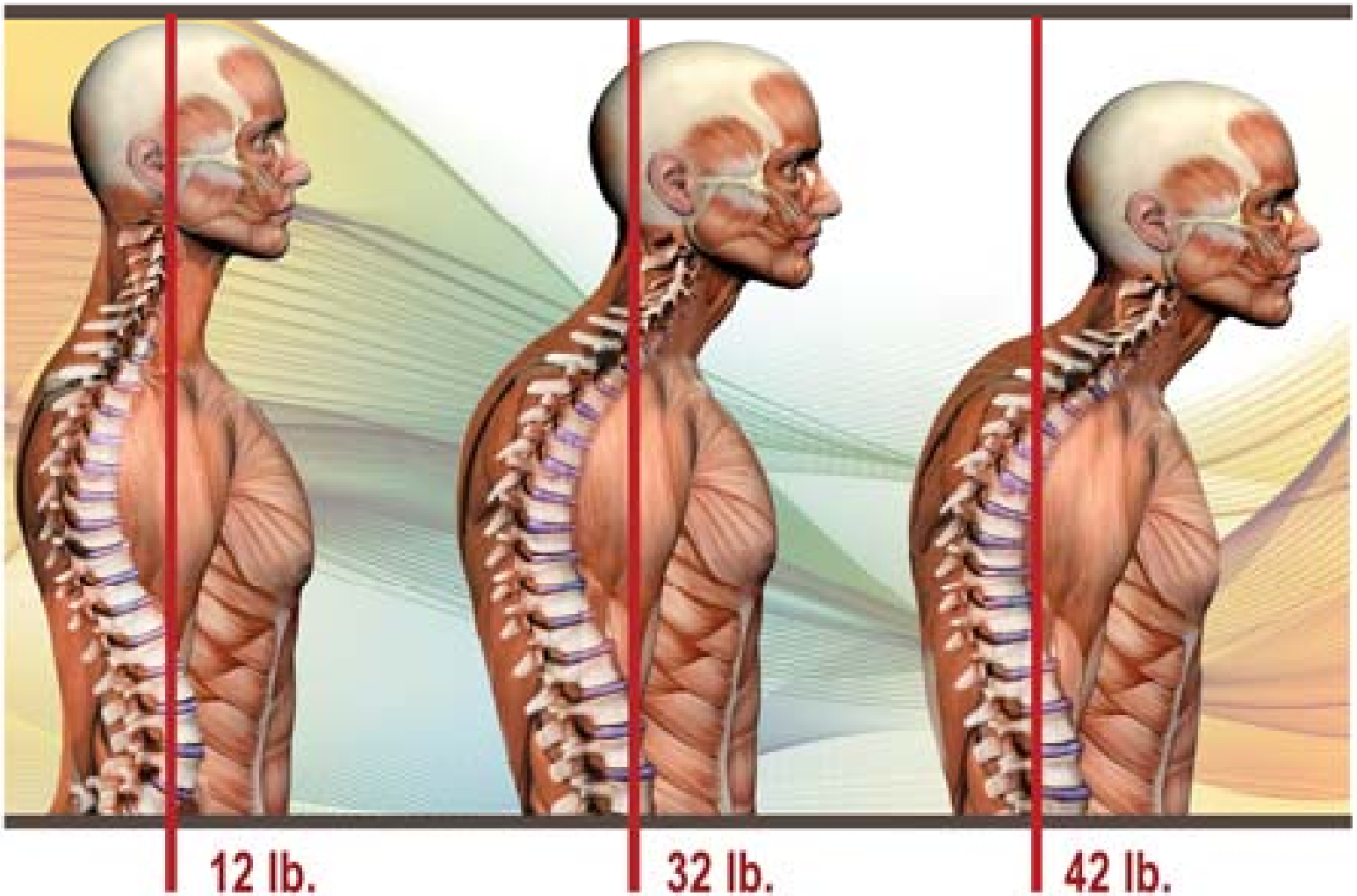

Figure 1

© 2010 www.erikdalton.com

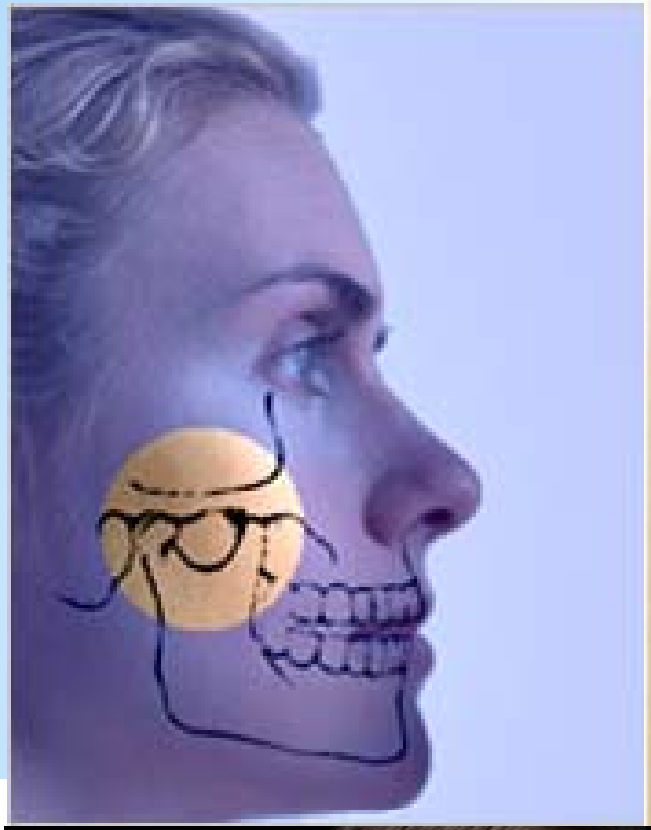

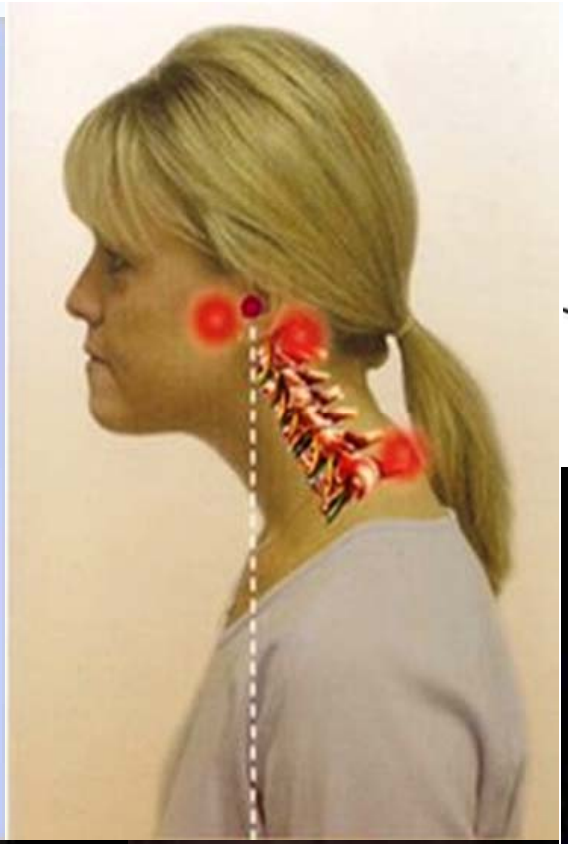

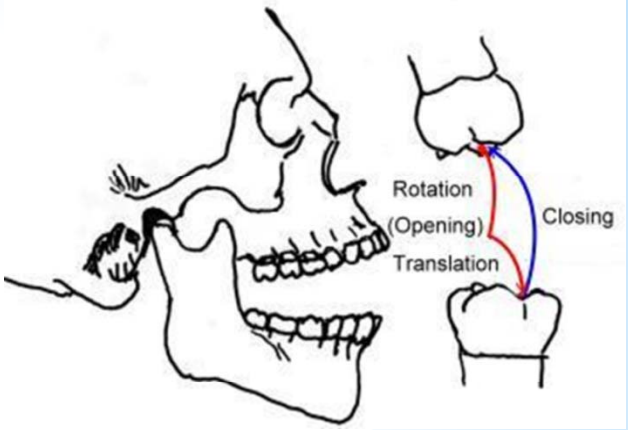
Rotation
(Opening)
Translation
Closing

During snoring, air flow is partially blocked.

WHAT IS THE OCCLUSAL PLANE?

* POSITION OF MAXIMUM INTERCUSPATION (MIP) OR CONTACT OF POSTERIOR TEETH

1. THE STATIC POSITION IS USED AS A REFERENCE GUIDE OF THE OCCLUSION

2. THE DYNAMIC POSITION HAS 3 DIMENSIONS THAT CAN RANGE UPTO 7mm;



*OCCLUSAL PLANE IN 2D CEPHALOMETRIC ANALYSIS

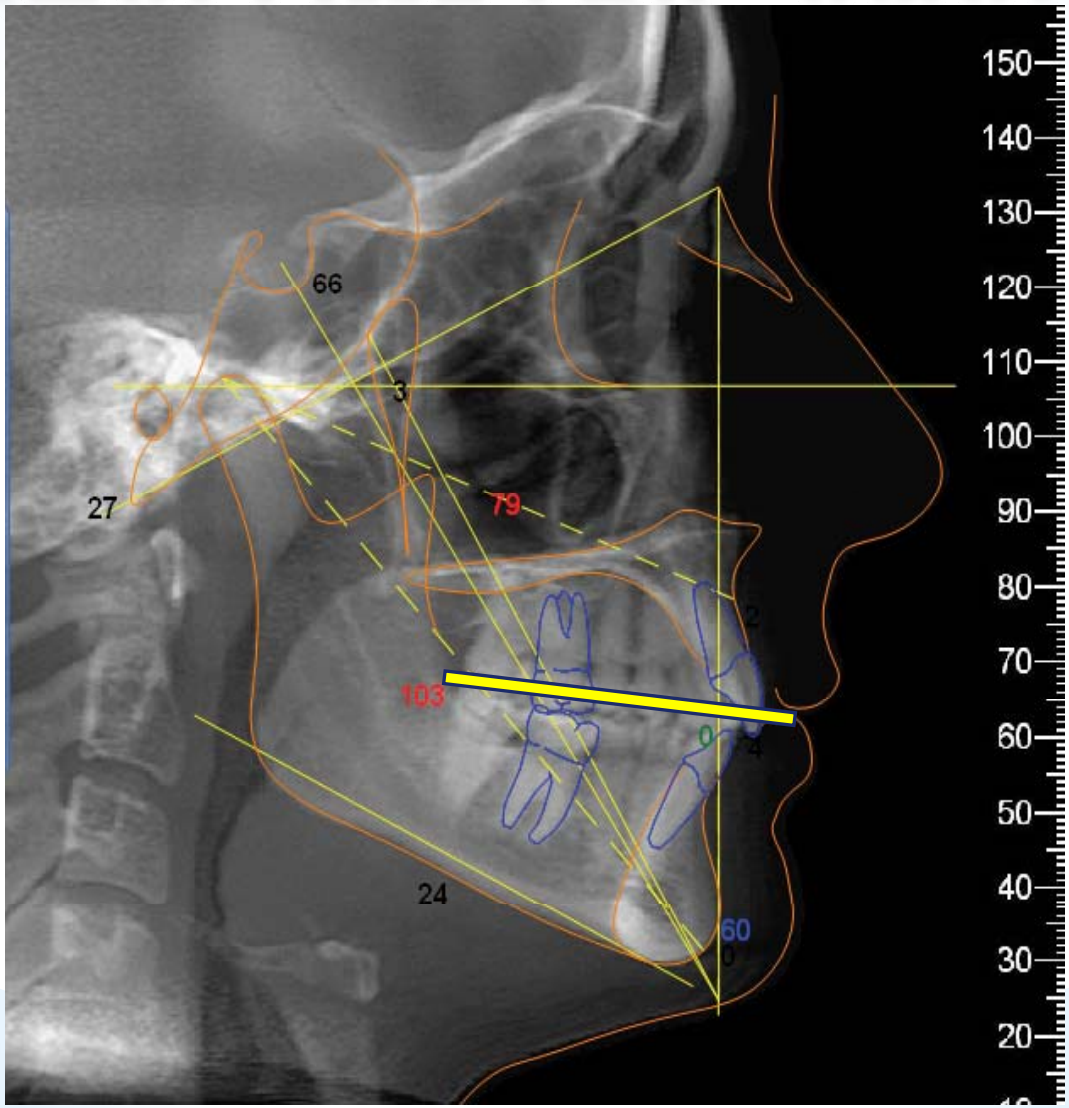

OCCLUSAL PLANE

*STANDARDIZATION TECHNIQUES

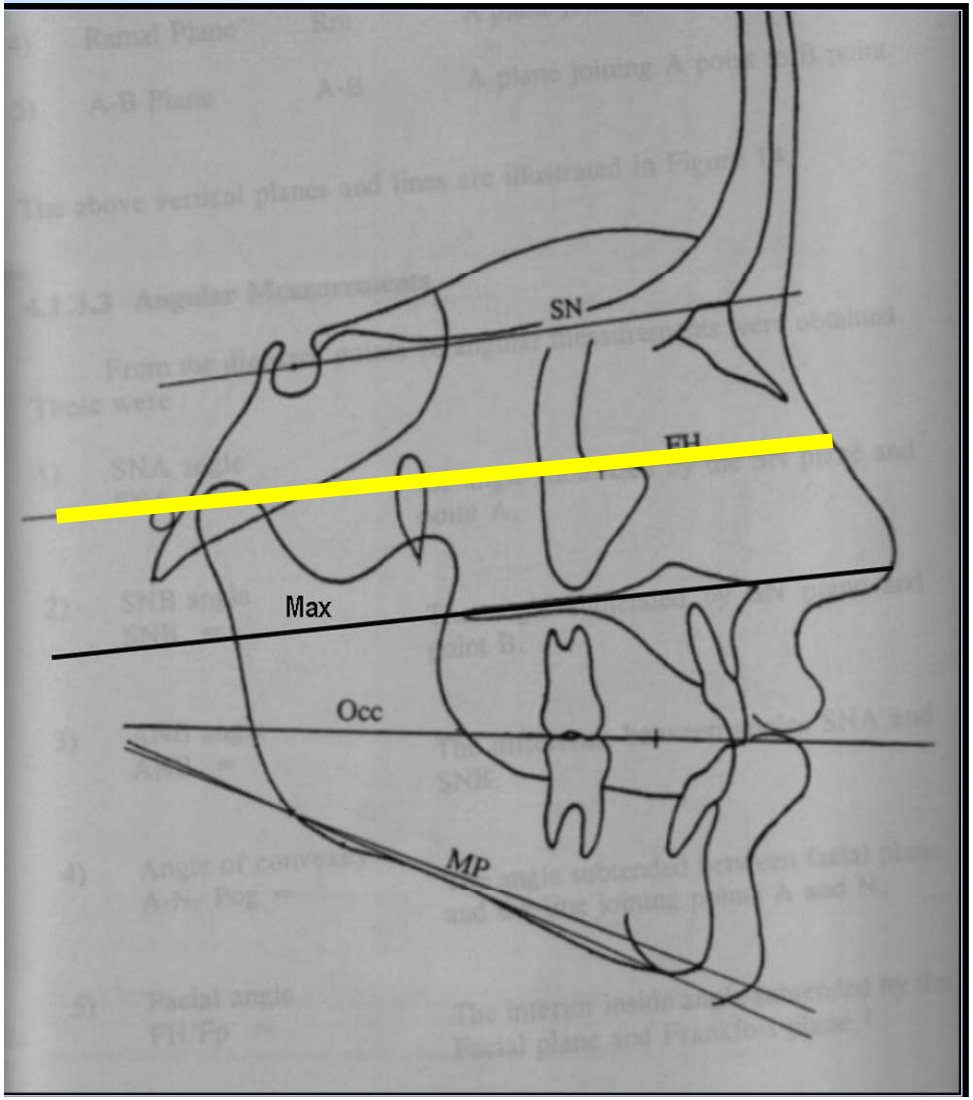

*FRANKFURT PLANE

*OCCLUSAL PLANE

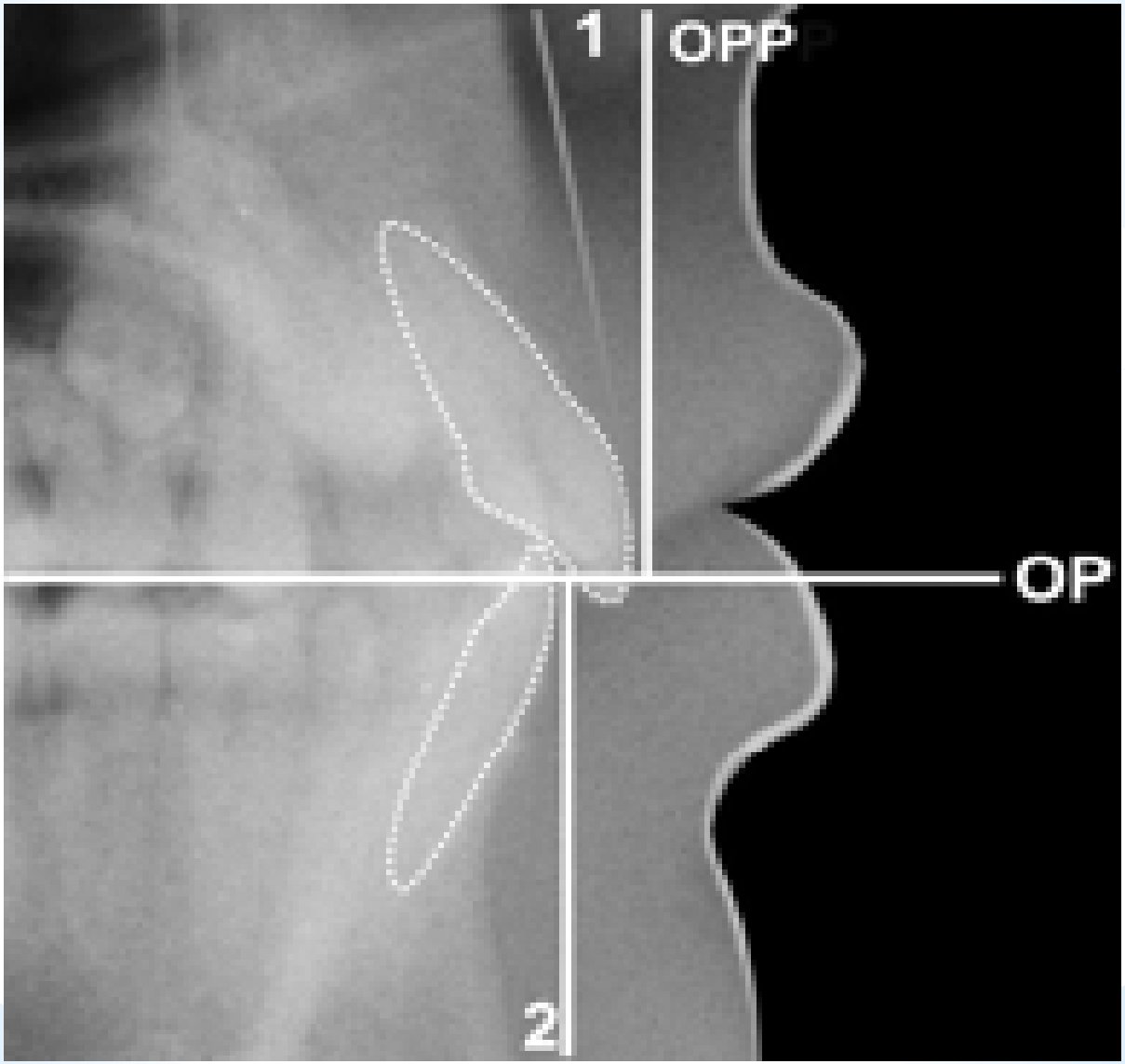

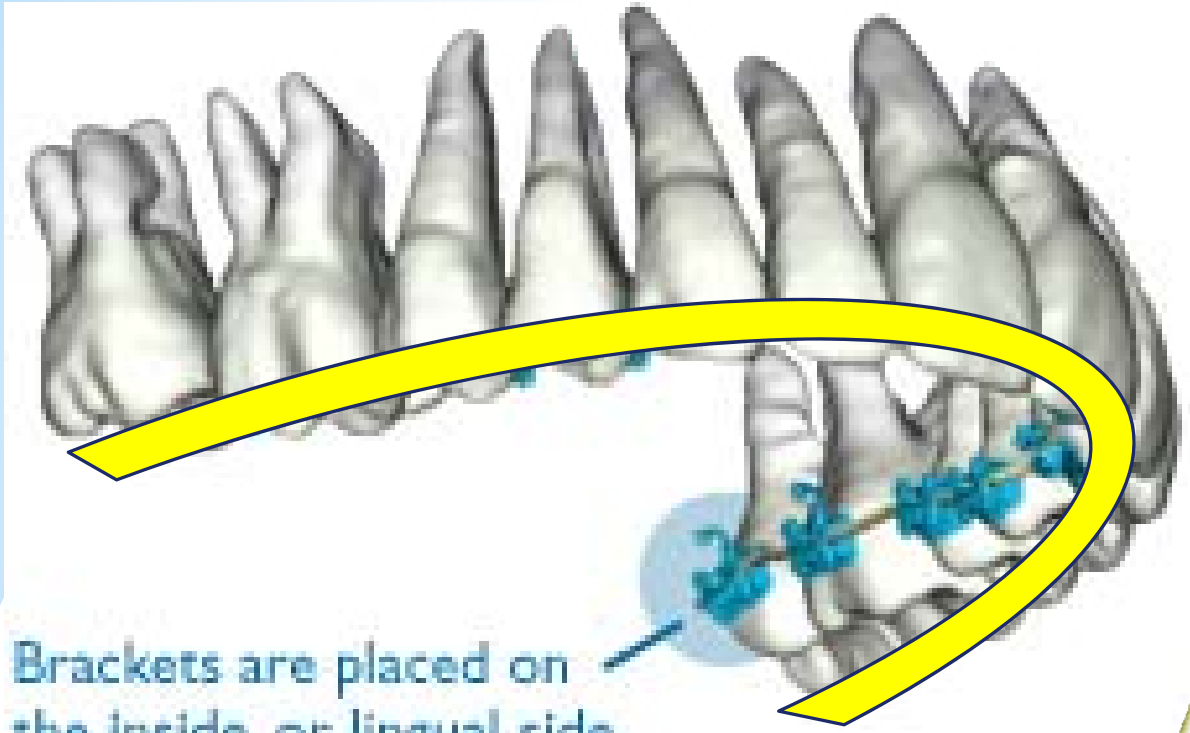

OCCLUSAL PLANE HAS A LINE, RANGE

* 3D OCCLUSAL CLOUD: RANGE OF OCCLUSAL CONTACT FROM MIP TO DISOCCLUSION

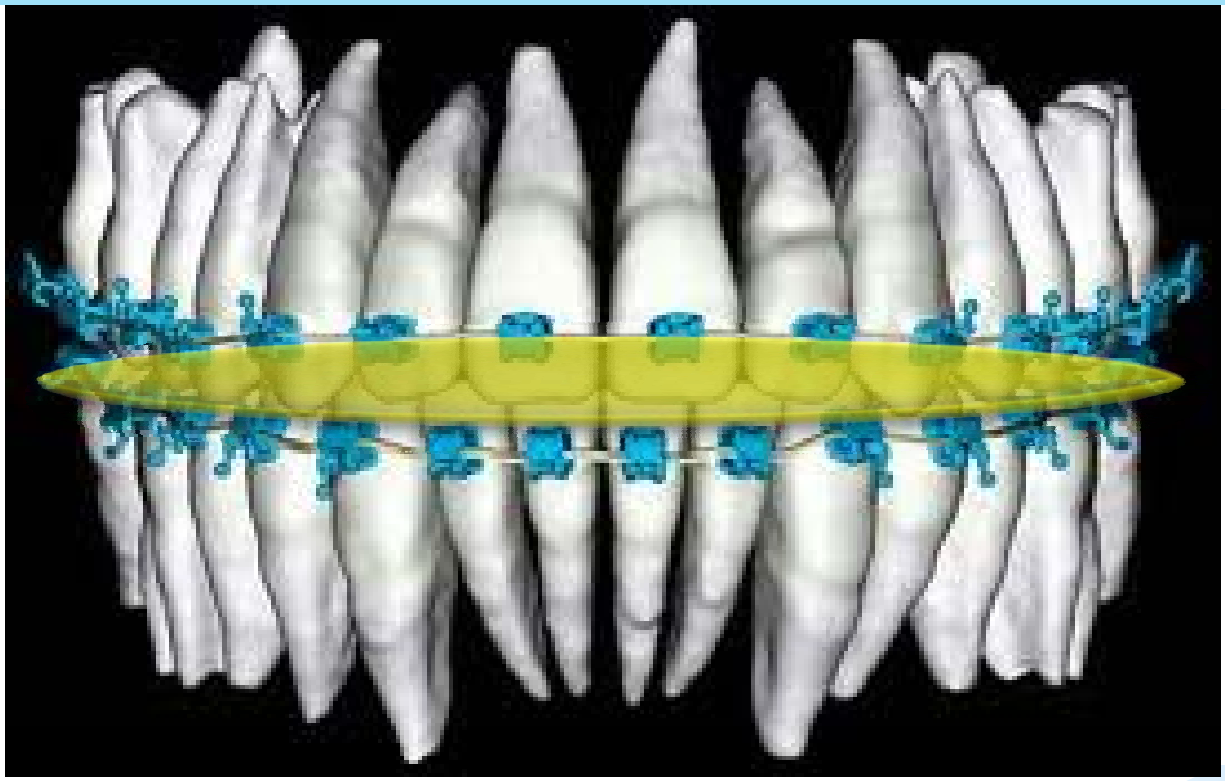

3D OCCLUSAL PLANE: STATIC POINT OF MAXIMUM INTERCUSPATION

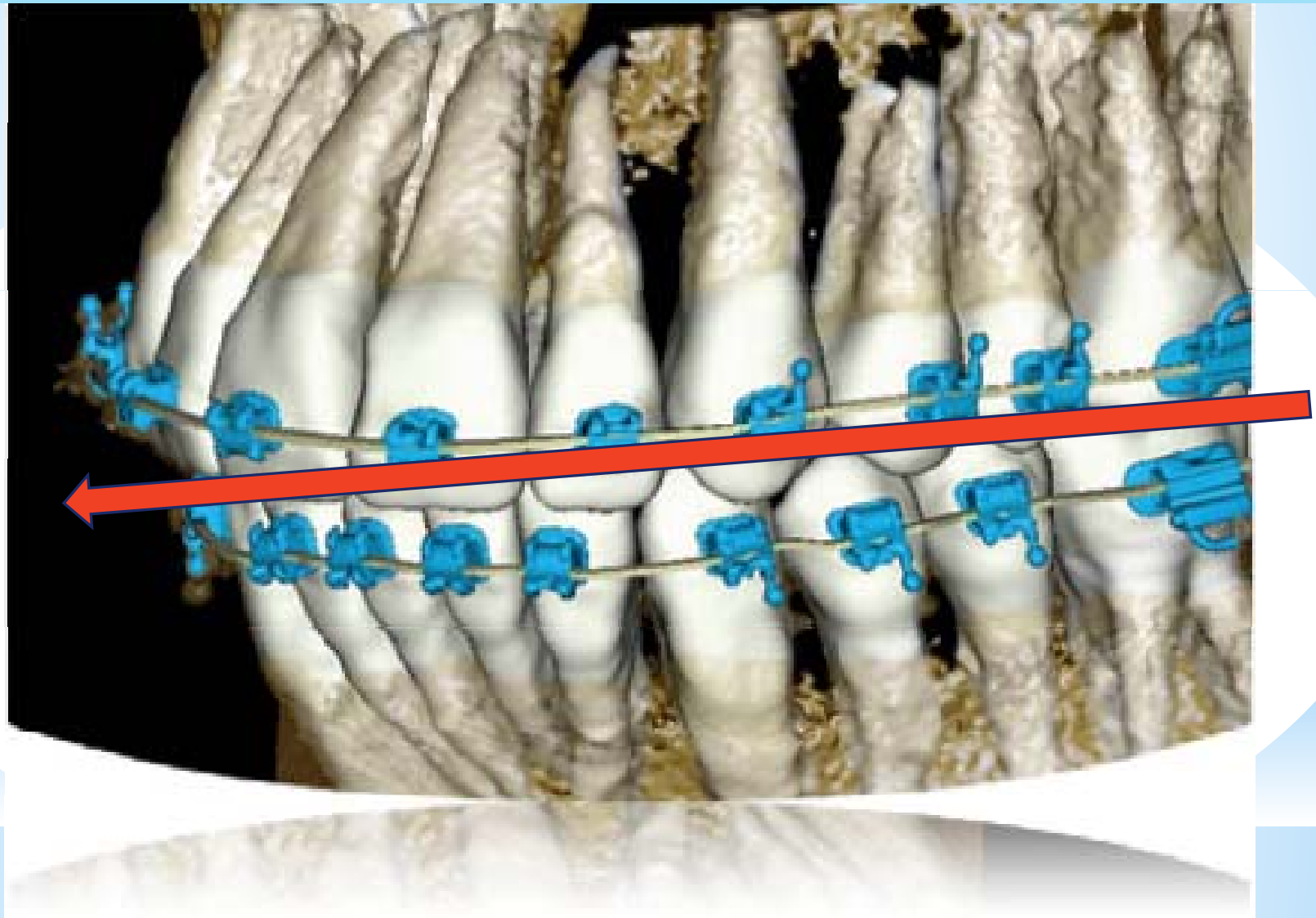

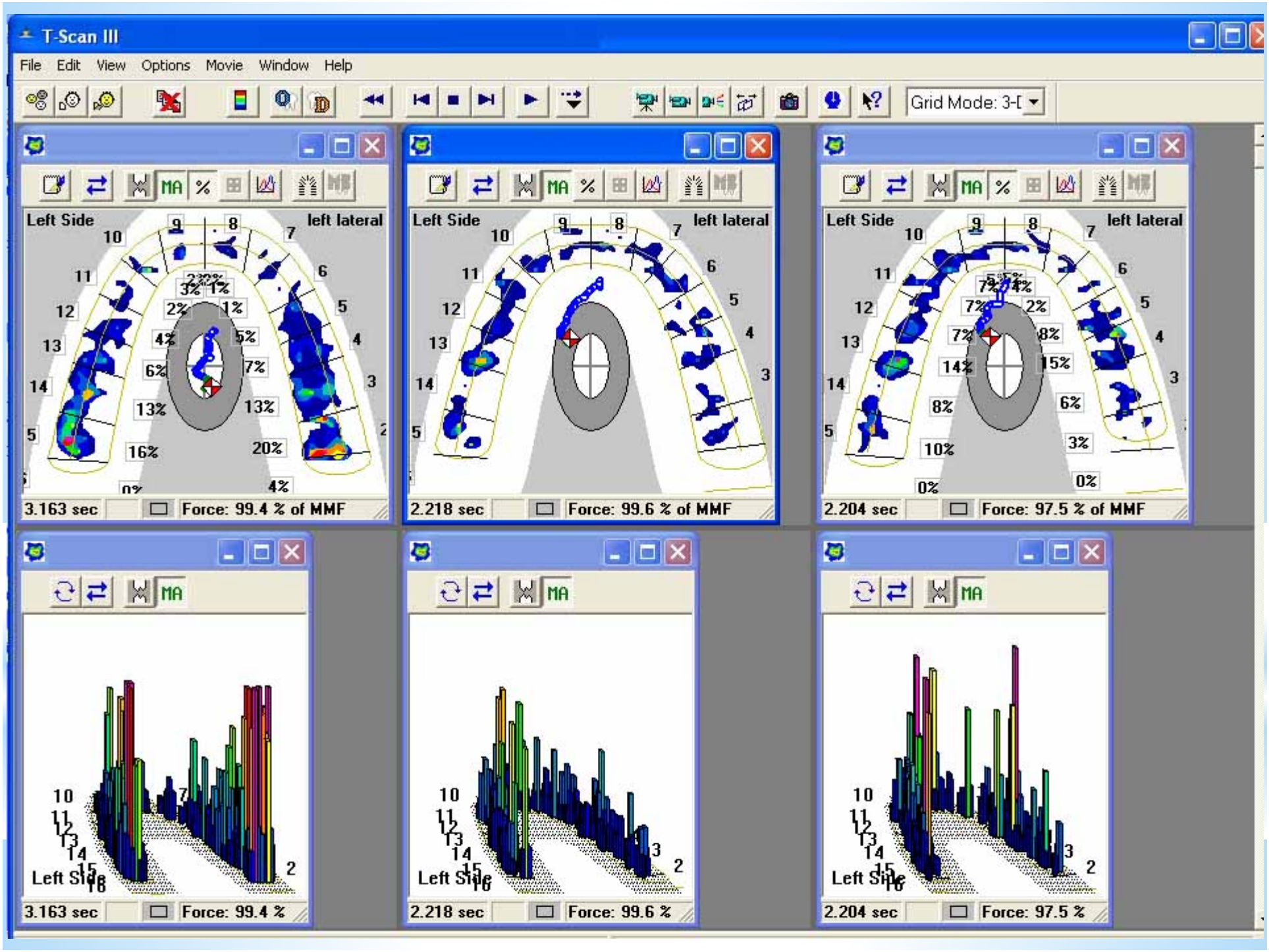
T-Scan III
File Edit View Options Movie Window Help
Grid Mode: 3-D
Left Side
left lateral
3.163 sec
Force: 99.4 % of MMF
2.218 sec
Force: 99.6 % of MMF
2.204 sec
Force: 97.5 % of MMF
Left Side
3.163 sec
Force: 99.4 %
2.218 sec
Force: 99.6 %
2.204 sec
Force: 97.5 %

* WHY IS THE OCCLUSAL PLANE IMPORTANT?

* FAILURE TO ACCURATELY ESTABLISH THE POSITION OF THE OCCLUSAL PLANE IN DIAGNOSIS AND TREATMENT PLANNING CAN HAVE A DAMAGING EFFECT ON THE DENTITION.

FACIAL BALANCE (ESTHETICS)

ESTABLISHED AROUND THE ORIENTATION OF THE OCCLUSION

FUNCTIONAL OCCLUSION DISORDERS

ESTABLISHED AROUND THE POSTURE

* MOVEMENTS OF THE LOWER JAW (MANDIBLE)

* WHAT FACTORS EFFECT OCCLUSAL PLANE?

* GENETIC DISORDERS
* CRANIOFACIAL MORPHOGENESIS
* ENVIRONMENTAL FACTORS
* IATROGENIC: DENTAL INTERVENTION

* ADVANCES IN 3D DIAGNOSTICS AND TREATMENT PLANNING

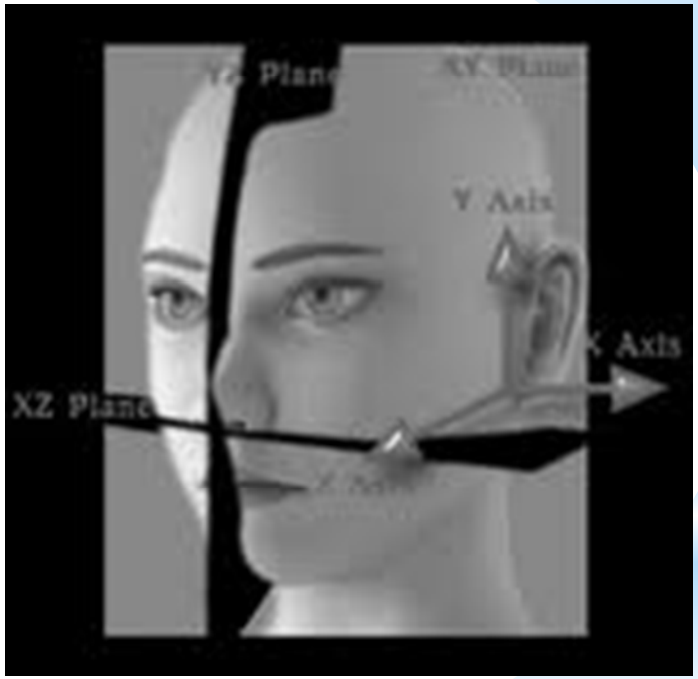

* VIRTUAL 3D MODEL OF HEAD AND NECK

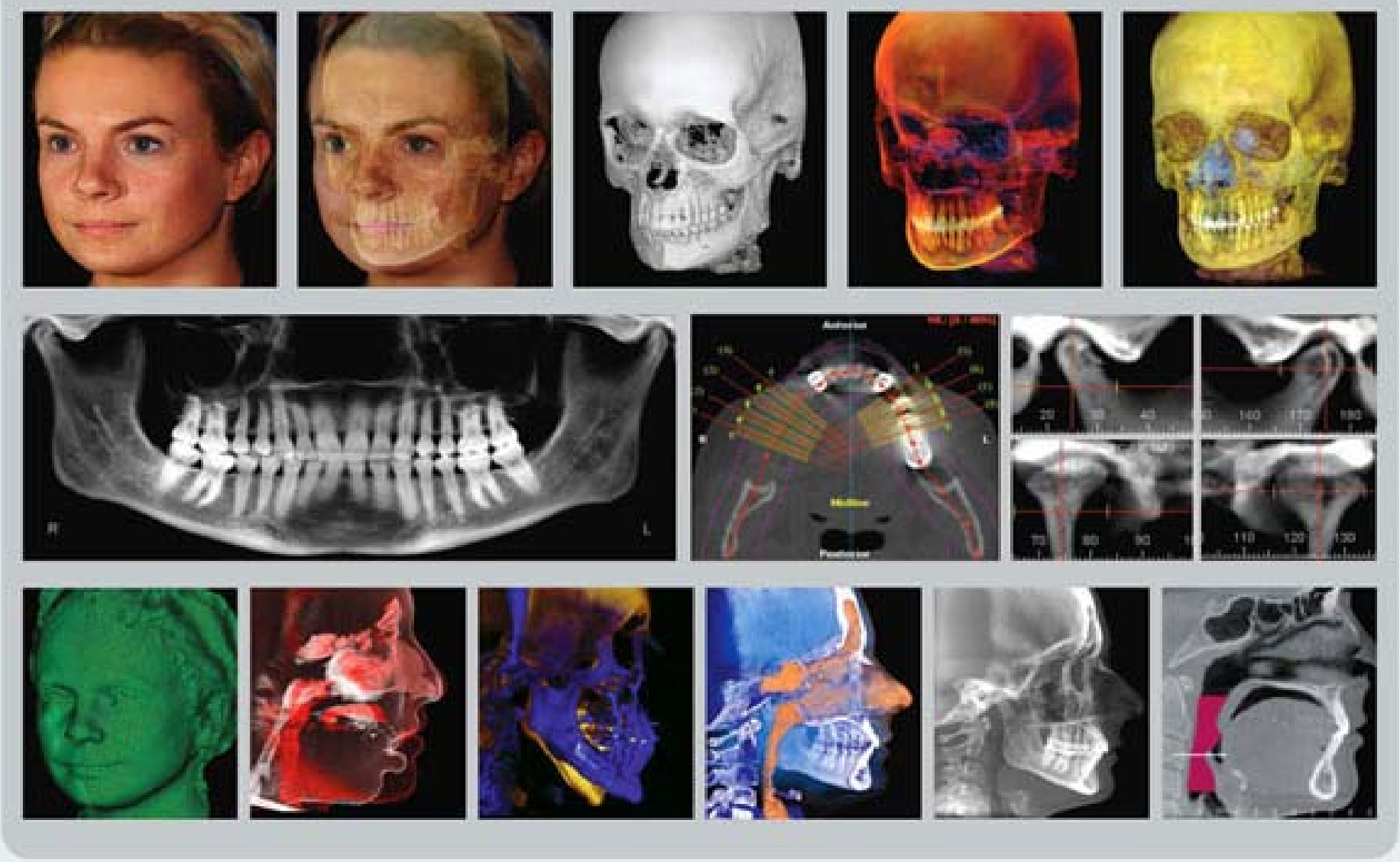

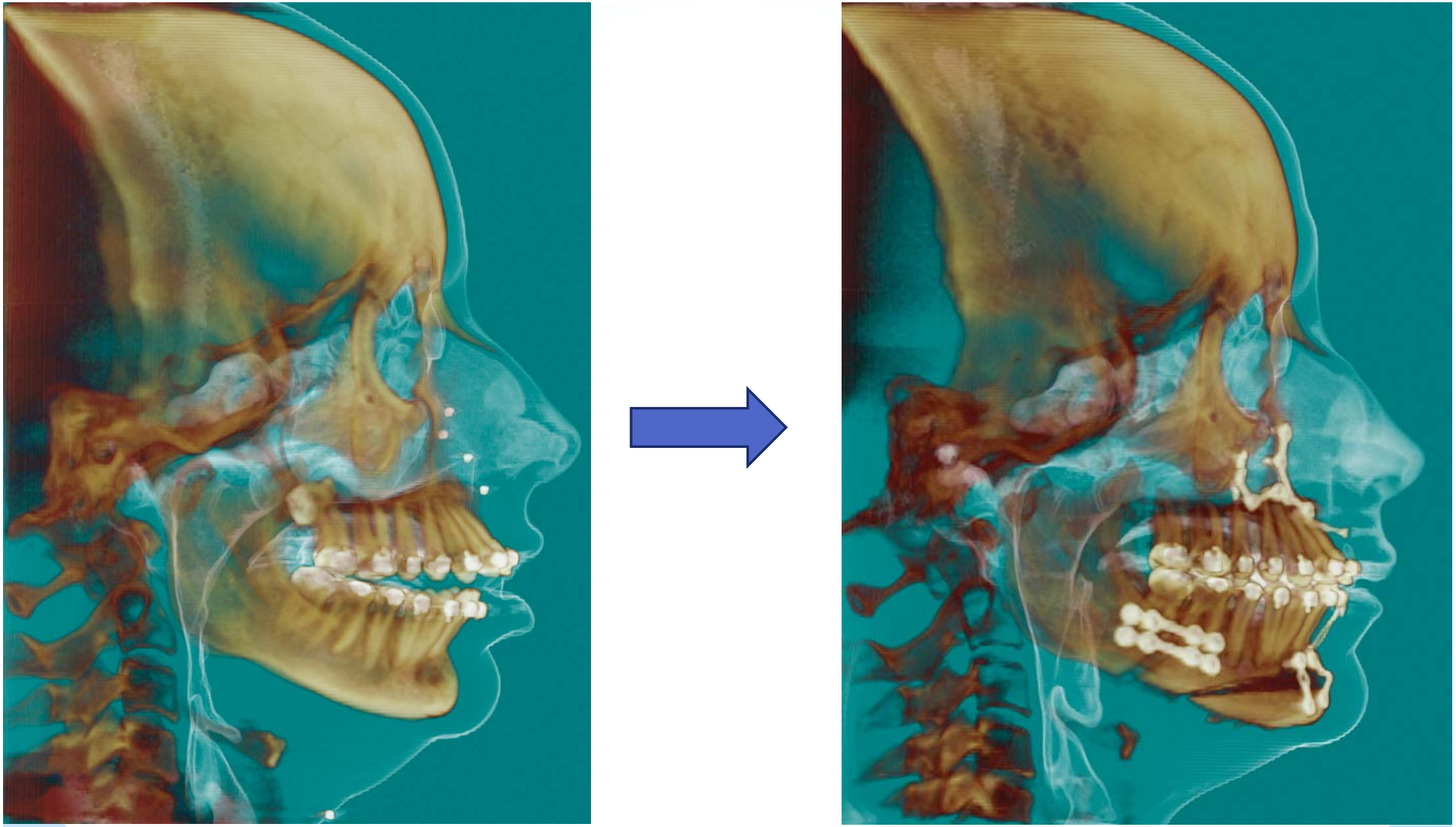

*Translucent soft-and hard-tissue images of pre- & post-surgery case

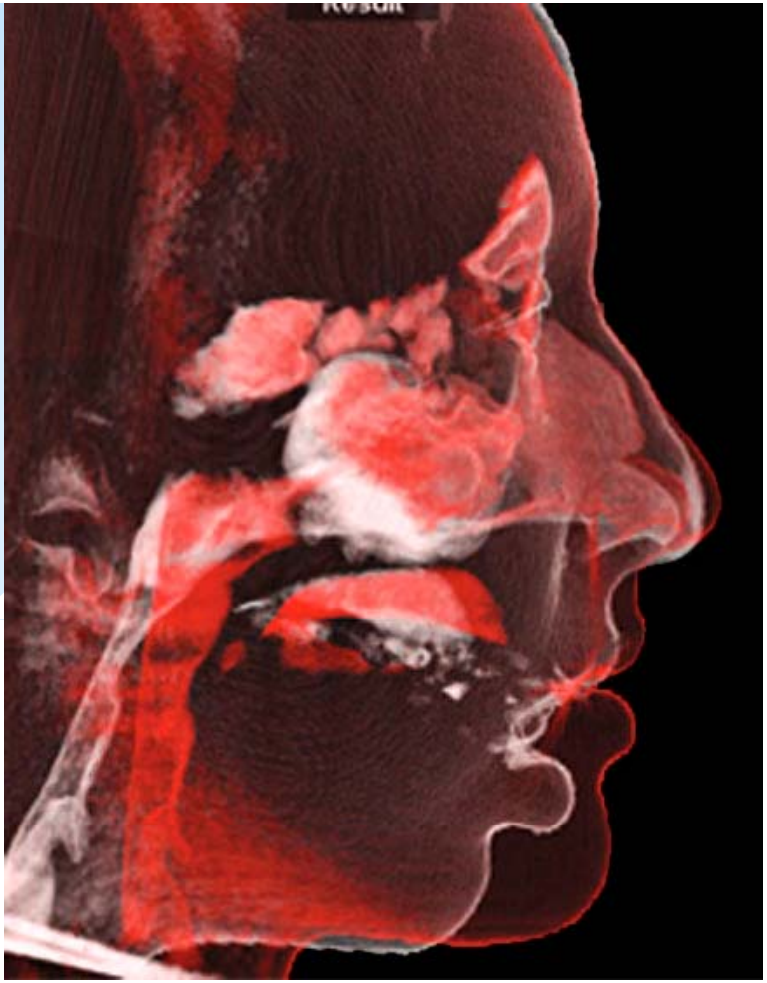

*PROGRESS SUPERIMPOSITION IN 3D

* DISCONNECT WITH 3D PHOTOS,3D CBCT… …..and NATURAL HEAD POSITION

* NEW METHOD OF RECORDING NHP

JOURANL OF ORAL MAXILLOFACIAL SURGERY, JANUARY 2011

* JOURANL OF ORAL MAXILLOFACIAL SURGERY, 2011

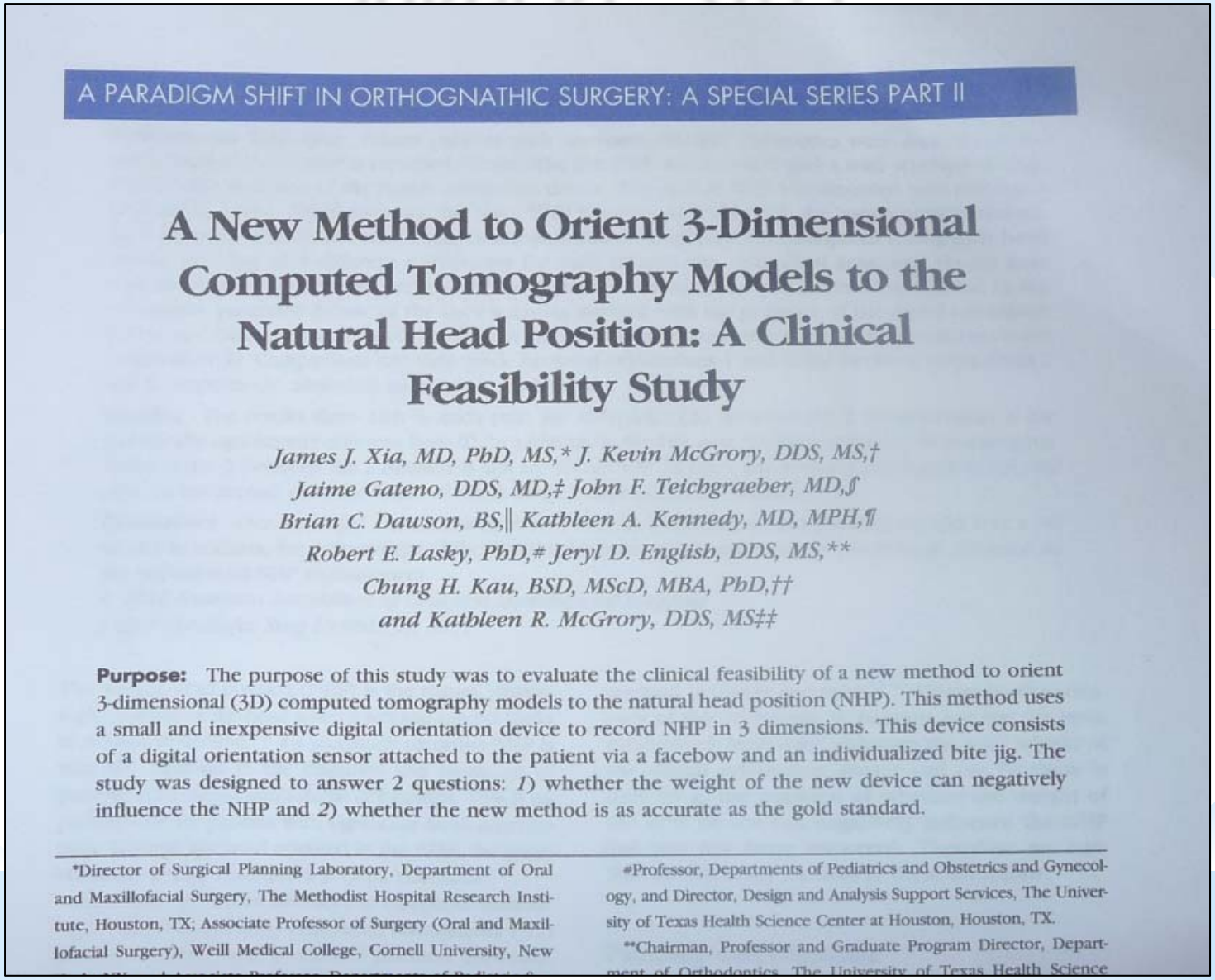

A PARADIGM SHIFT IN ORTHOGNATHIC SURGERY: A SPECIAL SERIES PART II

A New Method to Orient 3-Dimensional Computed Tomography Models to the Natural Head Position: A Clinical Feasibility Study

James J. Xia, MD, PhD, MS, J. Kevin McGrory, DDS, MS,†*
Jaime Gateno, DDS, MD,‡ John F. Teichgraeber, MD,§
Brian C. Dawson, BS,‖ Kathleen A. Kennedy, MD, MPH,¶
*Robert E. Lasky, PhD,# Jeryl D. English, DDS, MS,***
Chung H. Kau, BSD, MScD, MBA, PhD,††
and Kathleen R. McGrory, DDS, MS‡‡

Purpose: The purpose of this study was to evaluate the clinical feasibility of a new method to orient 3-dimensional (3D) computed tomography models to the natural head position (NHP). This method uses a small and inexpensive digital orientation device to record NHP in 3 dimensions. This device consists of a digital orientation sensor attached to the patient via a facebow and an individualized bite jig. The study was designed to answer 2 questions: *1*) whether the weight of the new device can negatively influence the NHP and *2*) whether the new method is as accurate as the gold standard.

*Director of Surgical Planning Laboratory, Department of Oral and Maxillofacial Surgery, The Methodist Hospital Research Institute, Houston, TX; Associate Professor of Surgery (Oral and Maxillofacial Surgery), Weill Medical College, Cornell University, New

#Professor, Departments of Pediatrics and Obstetrics and Gynecology, and Director, Design and Analysis Support Services, The University of Texas Health Science Center at Houston, Houston, TX.

**Chairman, Professor and Graduate Program Director, Department of Orthodontics, The University of Texas Health Science



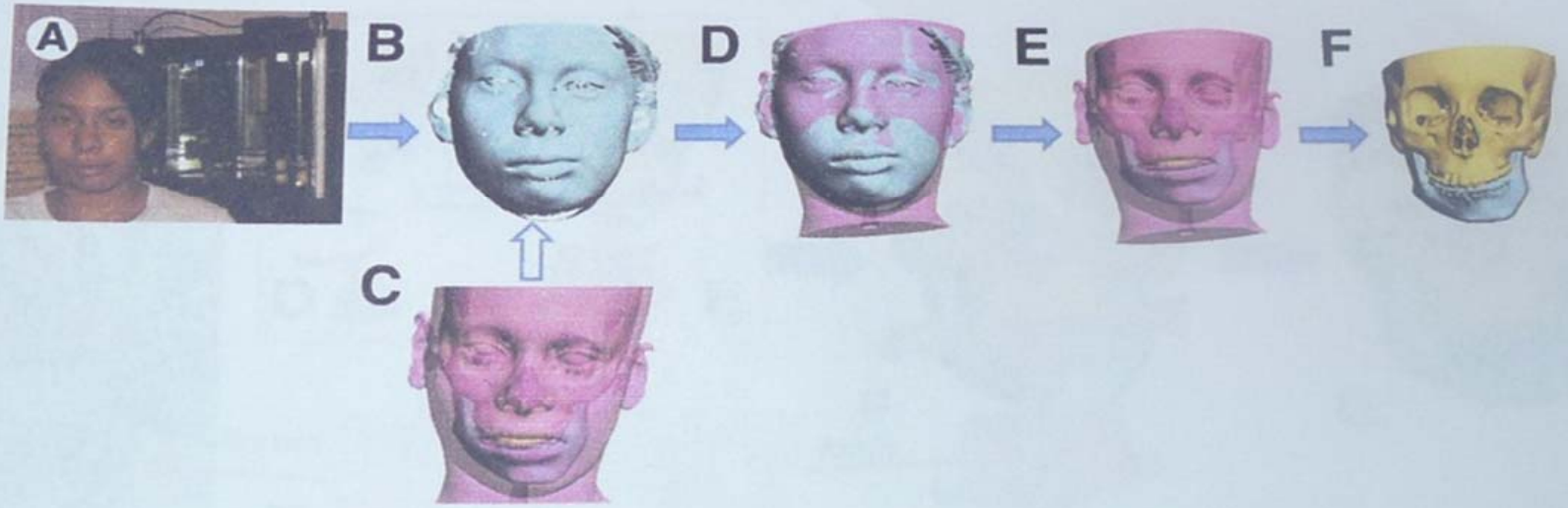

FIGURE 1. Laser scanning method. *A*, The patient sits on a calibrated chair that is positioned at the center of the laser scanner. *B*, A 3D facial image in the NHP is captured by the laser scanner. *C*, A 3D CT facial and bone (underneath the soft tissue) model of the patient's head. *D*, The recorded NHP is transferred to the 3D CT facial model by registering it to the 3D facial image in the NHP. *E*, Resultant 3D CT facial model in the NHP. *F*, Resultant 3D CT bone model in the NHP.

Xia et al. A New Method of Recording NHP. J Oral Maxillofac Surg 2011.

NEW DIRECTIONS?

* 3D/3T VIRTUAL ARTICULATOR
* MISSING PIECE IN THE PUZZLE IS THE ORIENTATION OF THE OCCLUSAL PLANE IN NHP, AND THE ABILITY TO REPRODUCE THE POSITION AT WILL OVER TIME
* LOCALIZATION OF THE OCCLUSAL PLANE IN REAL TIME WITH ABSOLUTE OCCLUSAL FORCES
* COMPUTER GENERATED OCCLUSAL PLANE
* CAD/CAM TECHNOLOGY

* ST. APOLLONIA DIED C 249 IN ALEXANDRIA, EGYPT

* SAINT APPOLONIA: VICTIM OF TORTURE



THANK YOU FOR YOUR ATTENTION