

1st Invitational Workshop on Body Area Network Technology
and Applications

Wireless Video Capsule Endoscopy

David Cave MD PhD

Professor of Medicine

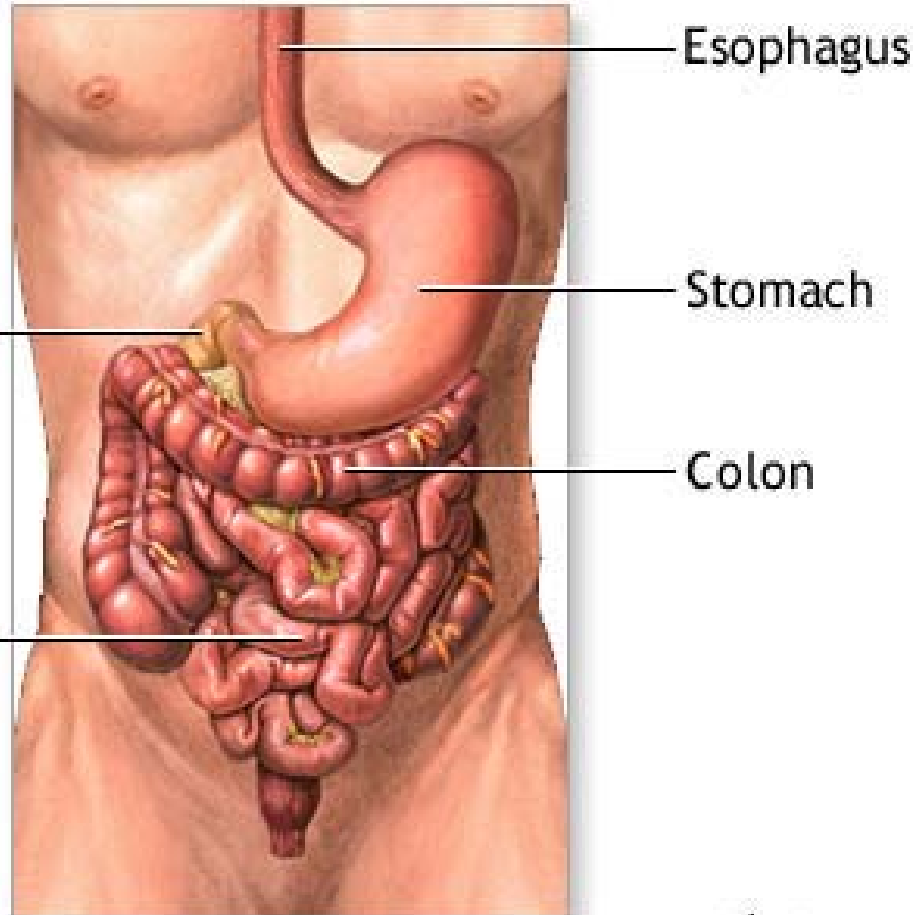
University of Massachusetts Medical School

Disclosures

David Cave

- Recipient of research funds from and consultant for Given Imaging
- Recipient of research funds from Intramedic
- Consultant for Olympus Corp

Anatomy of the small intestine



Tools available

Esophago-gastro-duodenoscopy

Push enteroscopy

Deep enteroscopy

Colonoscopy

Deep enteroscopy

What is Capsule Endoscopy?

- Capsule endoscopy (CE) allows for direct, non-invasive visual examination of the gastrointestinal tract
- Images are transmitted from a disposable, ingestible wireless video capsule and are downloaded for clinical review
- CE has become the gold standard in evaluating suspected disease of the small bowel

Evolution of Capsule Endoscopy

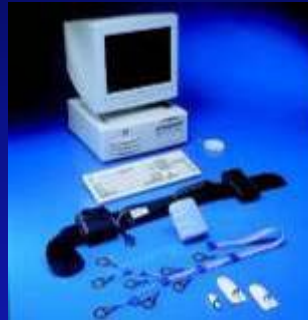1999

2000

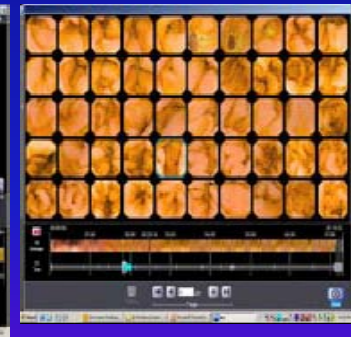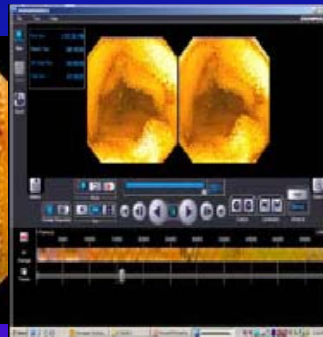
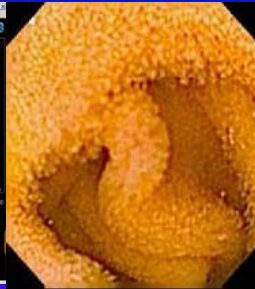
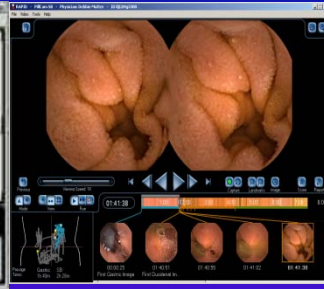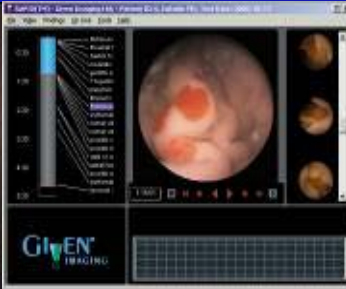2003

2007

Hardware



Software



Capsule



OMOM
Mirocam
Capsocam



Capsule Endoscopy Systems

Given PillCam SB2



Olympus EndoCapsule



Capsule Endoscopes

	IntroMedic MiroCam	Given Imaging SB / SB2	Olympus EndoCapsule
▶ Size	11x24mm	11x26mm	11x26mm
▶ Weight	3.4g	3.45g	--
▶ Resolution	320 x 320	256 x 256	--
▶ Rate	3 fps	2 fps	2 fps
▶ Time	11 hours	8 hours	8 hours
▶ Field of View	150°	140° / 156°	145°
▶ Communication	HBC	RF	RF
▶ Real Time Viewer	Yes	Yes	Yes

Clinical Applications for CE

(ASGE Technology Status Evaluation Report)

Small Bowel Capsule Endoscopy:

- Obscure GI bleeding including iron deficiency anemia (IDA)
- Suspected Crohn's disease
- Suspected small intestinal tumors and surveillance in patients with polyposis syndromes
- Suspected or refractory malabsorptive syndromes (celiac disease)

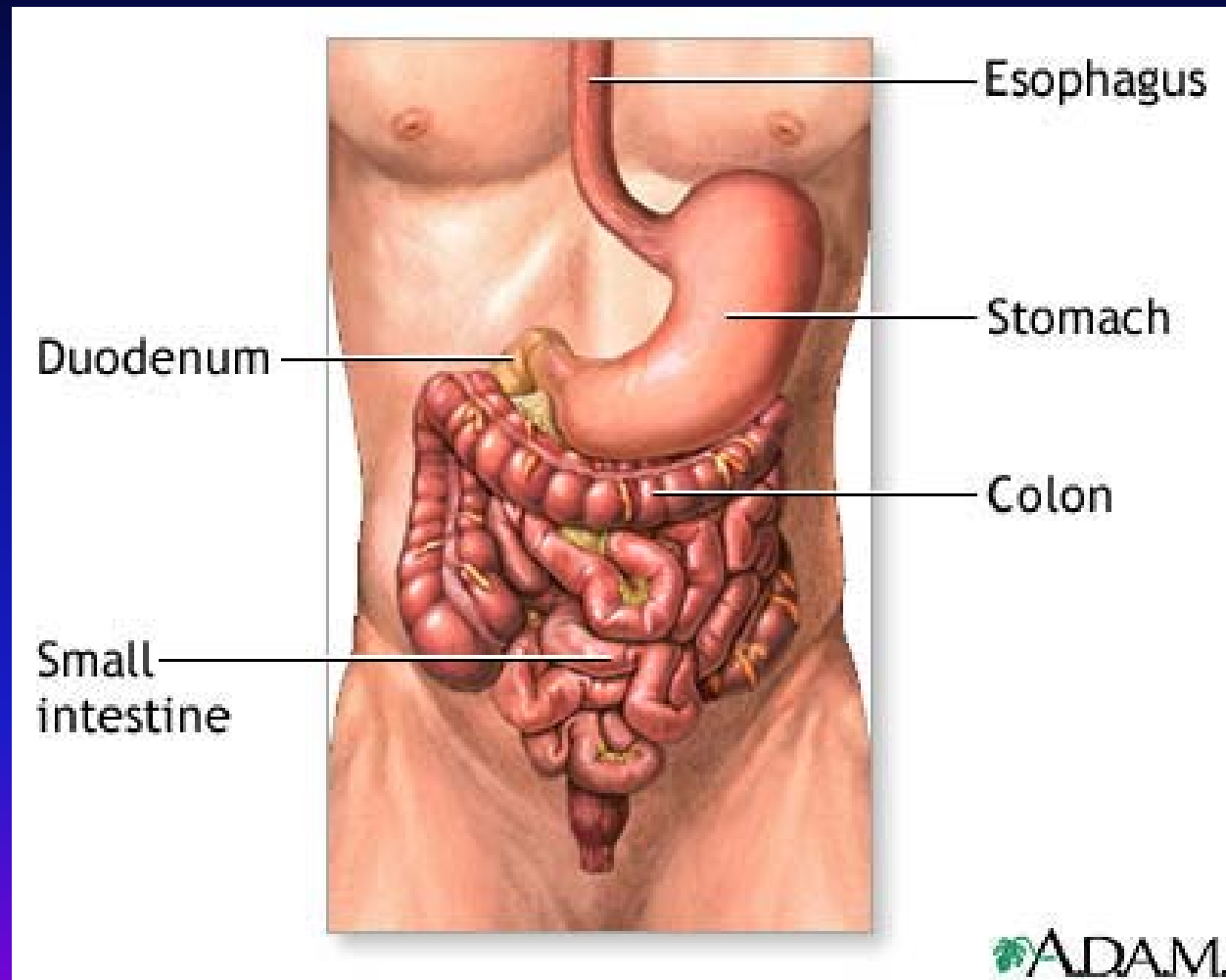
Clinical Applications for CE [Other]

- Chronic diarrhea
- Assessment of disease activity of Crohn's disease.
- Detection of strictures
- Abdominal pain?????

The Problem

- Where is the lesion/capsule?
- Current localization algorithms are not useful

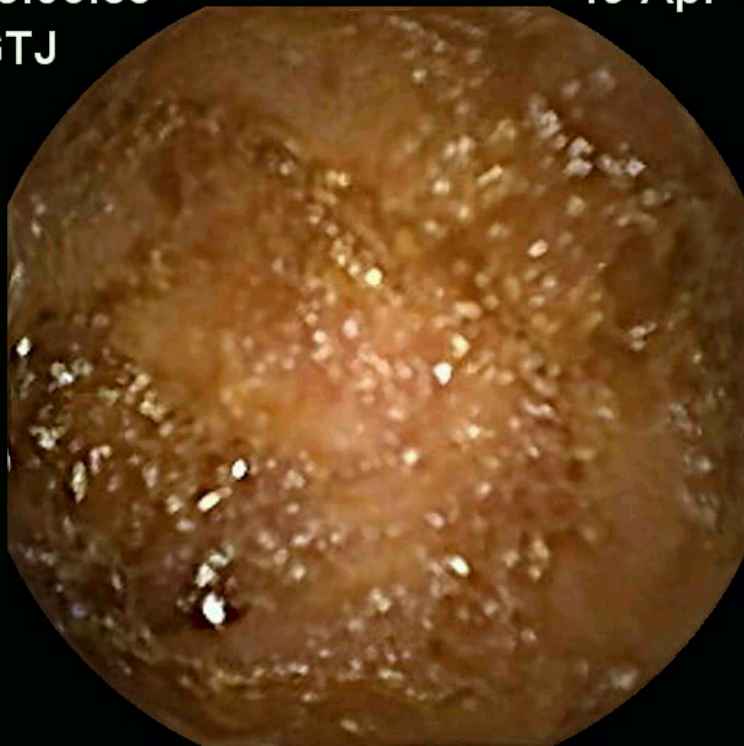Anatomy of the small intestine



05:06:53

19 Apr 11

GTJ



PillCam® SB 2

Video capsule desktop

The screenshot displays the RAPID Access software interface for a PillCam SB video capsule endoscopy. The window title is "RAPID Access - PillCam SB - Physician: - ID smPsPA3300". The interface includes a menu bar with "File", "Video", "Tools", and "Help".

The main viewing area shows a circular video feed of the gastrointestinal tract. Below the video is a control panel with a "Previous" button, a "Viewing Speed: 18" slider, and navigation buttons (back, stop, forward). To the right are buttons for "Capture", "Landmarks", "Image", "Score", "Report", and "Save".

A timeline at the bottom shows a duration of "00:57:42" and a color-coded progress bar from 0 to 9:00. Below the timeline are six thumbnail images of the video feed with timestamps: "01:08:31", "01:24:43", "01:25:31", "01:38:58", "01:39:58", and "01:4".

In the bottom-left corner, there is a diagram of the human digestive system with a capsule icon. Below it, the text reads: "Passage Times: Gastric 0h 17m SB 7h 18m".

What do we use to assess position of the VCE?

- Time
 - Assumption: motion is linear between pylorus and ileo-cecal valve
- Factors that alter motility
 - Disease process
 - Adhesions
- Blood stimulates gut motility
- Transit incomplete 15-25% of the time

Assessment of motor function

- New insight into intestinal motor function via noninvasive endoluminal image analysis
- Malagelada C et al; Gastroenterology 2008 Oct;135(4):1155-62

Conclusions

- Is there a methodology that could improve location of a VCE?
- 1- longitudinally
- 2- in 3 D with reference to fixed points